



RESEARCH ARTICLE

EVALUATION OF INTRA-OPERATIVE ULTRASOUND IN ASSESSING CLEAR MARGIN IN BREAST CONSERVATIVE SURGERY

Ahmed Shalaby^{1,*}, Matei Dordea¹, Marwa Badawi¹, Ashwin Rajenderia¹ Alyaa Shamardel² and Khaled Nouredin³

¹University hospital of North tees And Hartlepool NHS Foundation Trust

² Kettering General Hospital NHS Foundation Trust

³Southend University Hospital NHS Foundation Trust

ARTICLE INFO

Article History:

Received 25th January, 2020

Received in revised form

19th February, 2020

Accepted 27th March, 2020

Published online 30th April, 2020

Keywords:

Search strategy,
Data extraction,
Advantages of IOUS.

ABSTRACT

Aim: Breast conservative surgery (BCS) and oncoplastic procedures are becoming more and more popular, providing better aesthetic outcome but one of the main draw-back of these procedures is involvement of the margin and return to theatre, causing undesired economic and cosmetic outcome in addition to psychological burden on the patients. Frozen section can decrease incidence of involved margin however, it is not always available in addition to increasing the cost. Using intra-operative ultrasound (IOUS) is a proposed solution to overcome this dilemma. **Methods:** In this systematic review, publication between 2001 and 2019 assessing the use of intra-operative US for margin clearance were identified in Medline Embase Cinahl Amed and the Cochrane library, with the primary outcome looking into margin involvement and return to theatre and secondary outcome as cosmetic outcome. And the volume of removed breast tissue. 7 papers were identified for this systematic review. These papers were critically appraised using PRISMA guideline, with main focus on margin involvement, and also looking into the volume of specimen removed. **Conclusion:** Intra-operative ultrasound can decrease return to theatre and improve surgical margin as well as cosmetic outcome and patient satisfaction. On the other hand, ultrasound overestimated the pathology margins in most cases. Margin overestimation by ultrasound may lead the surgeon to incorrectly believe that the excised margins are appropriate. The overestimation of the majority of the tumour margins may be explained in part by the tendency of ultrasound to underestimate the pathologic tumour diameter.

Copyright © 2020, Ahmed Shalaby et al. This is an open access article distributed under the Creative Commons Attribution License, which permits unrestricted use, distribution and reproduction in any medium, provided the original work is properly cited.

INTRODUCTION

Because of routine screening mammography and increased public awareness, breast cancer is increasingly detected at an earlier stage. For women with operable breast cancer, surgical resection options are breast conservation surgery (lumpectomy) and mastectomy. For many women in whom lumpectomy is feasible, a breast conservation approach is the preferred option (Houssami *et al.*, 2014). One of the primary goals of breast-conserving surgery is to obtain cancer free margin. Margins positive or focally positive for tumor cells are associated with a high risk of local recurrence, and in the case of tumor positive margins, re-excision or even mastectomy are sometimes needed to achieve definite clear margins. For focally positive margins, either second surgery or additional boost radiotherapy should be considered. (Eva Singletary 2018). Re-excision surgery of the tumor bed has a negative impact on cosmesis.

This is mainly as a consequence of the increased total volume of tissue excised from the breast. There is no limit to the number of re-excisions that a patient can have to achieve complete removal of all invasive and in situ disease, but with the greater number of re-excisions more tissue is removed and so the likelihood of a good cosmetic result decreases (Coopey *et al.* 2011). Intra-operative frozen section can be used as a planning strategy for the surgeon as to which direction requires a greater excision margin for safety by using the pathologist's report. However, the hospital has to employ the pathologist, the result is also at the discretion of the pathologist, and this step can add approximately 20–30 minutes to the operating time. Additionally, and perhaps most significantly, some authors have concluded that IFSA may not be reliable for the detection of ductal carcinoma in situ (DCIS). (Thill *et al.* 2014). Various imaging modalities have been used to locate and stage tumors before surgery and to locate and remove tumors and masses during surgery. Ultrasound has particularly lent itself to both preoperative and intraoperative use (Stargen & O'Neil 1998). US guidance gives the advantage of resecting less normal tissue while maintaining the clear margins with

*Corresponding author: Ahmed Shalaby,

University hospital of North tees And Hartlepool NHS Foundation Trust.

both palpable and non-palpable masses (Ahmed *et al.*, 2013). It has been shown to be feasible and, in some series, even superior to the gold standard technique of needle localization (Besic *et al.*, 2009).

Advantages of IOUS: Intraoperative ultrasound guided surgery (IOUS) has extensively shown to be a more effective tool compared to wire localization (WL) and palpation-guided surgery (PGS) (2,3). It also improves rates of negative margins, consequently reducing the need of second surgeries (4,5,6). In addition, The COBALT study showed a significant reduction in the volume excised when using IOUS as compared to PGS (38 cm³ vs. 57 cm³, p=0.002) (7)

Population	Breast conservative surgery Breast removal surgery Oncoplastic
Intervention	Intra-operative Ultrasound Intra-operative Sonogram Intra-operative Sonography
Observation/Outcome	Clear margin Safety margin Oncological clearance

MATERIALS AND METHODS

Search strategy: Publications through electronic databases including (MEDLINE EMBASE CINAHL AMED and The Cochrane library) were searched without time limit till 2019 using Boolean operators ‘‘AND’’ and ‘‘OR’’ to run the search. The extracted articles were organized, duplicate articles were deleted, then 2 reviewers assessed the titles and abstracts of search results independently and selected potentially-relevant studies according to the main question (Table 1). The articles that were deemed to be irrelevant to the research objectives were excluded. Then, the full texts of the selected articles were gathered.

Selection criteria & outcome measures: Both prospective and retrospective studies were included studies in English were searched for and studies in other languages was excluded. Main inclusion criteria for this study was (a). female patient undergoing breast conservative surgery (include wide local excision (WLE) and level 1 oncoplastic procedure (b). female patient with level 2 oncoplastic surgery. (c) ductal carcinoma in situ (DCIS) and Invasive cancer.

Main exclusion criteria were (a) Patients undergoing modified radical mastectomy

(b) Male patients as the standard procedure is mastectomy not breast conserving surgeries.

Primary outcomes

- To assess margin positivity rates in patients undergoing breast conservation surgery by intra-operative ultrasound guidance method
- Local recurrence rate
- Return to theatre for involved margins

Secondary outcomes: included

- Cosmetic outcome and quality of life in patients undergoing breast conservation surgery using intra-operative ultrasound guidance method.
- Volume of removed breast tissue.

Assessment of methodological quality: The articles selected for the review will be individually assessed for their external and internal validity. Two review authors will independently critically appraise the internal validity and external validity of the included studies. This will be assessed according to the criteria of Critical appraisal tools from the Cochrane Collaboration and the Critical Appraisal Skills Program (CASP) for RCT and Non-RCT. Another qualitative method of assessing data that will be used for Randomised controlled trials is (Jadad scoring system) (Jadad *et al.* 1996). The Newcastle-Ottawa Scale (NOS) (Ohri.ca, 2016) will be used to assess the observational studies.

Data extraction: A standardized excel data extraction form was prepared and used to extract data from the included papers. Data on the population, study characteristics and results will then be extracted independently by two review authors. Any disagreement will be discussed, and a third review author consulted if disagreements persist.

RESULTS

Based on the exclusion criteria and removal of duplicated results 37 studies were included after first selection. All articles were subsequently selected on title, abstract, and full text. Out of these 37 studies 7 publications met the eligible inclusion criteria for the study. The total number (first and second selection) Identification, screening, eligibility, and inclusion details all are shown in PRISMA flow chart (Fig. 1)

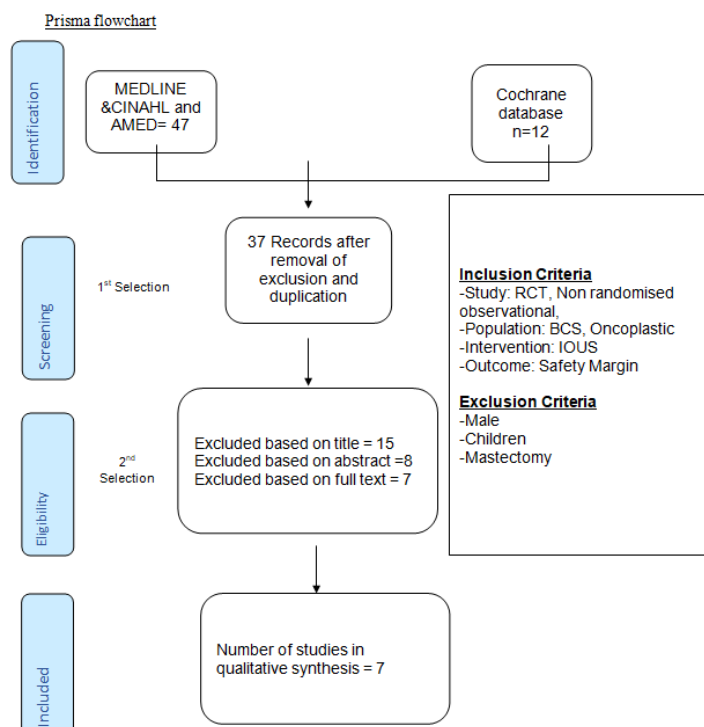
DISCUSSION

The need for second surgery was mentioned in all 7 studies. Four studies (Esqueva *et al.*, Moore *et al.* Ramos *et al.* and Karnalik *et al.*) showed that IOUS can reduce need for second surgery. However, Moore *et al.* included patients with DCIS in his study which may have resulted in his conclusion of superiority of US. Ramos *et al.* and Karnalik *et al.* showed that IOUS can improve surgical margin but their results can be attributed to the fact that US underestimate clear margin and result in removing excess breast tissues. Only Esqueva *et al.* RCT showed that IOUS is efficient method in detecting clear margin without underestimation of the clear margin. The COBALT trial and Larson *et al.* and Fisher *et al.* findings were that IOUS does not improve surgical margin when compared to control group. The total number of patients included in all 7 studies was 1166 number of those, patients who had intra-operative ultrasound was 711 patients.

The number of the pooled patients is significantly higher than any individual study individual which is one of the major advantages when performing systematic review. All seven studies mentioned the rate of safety margin involvement after performing breast conservative surgery, all the studies used ultrasound as an intra-operative radiological method in determining margin involvement, one study (Larson *et al.*) used additional radiological tool beside US in assessing the margin which was mammogram. Volume of breast tissue removed was reported in studies. cosmetic outcome and patient satisfaction were assessed in 3 papers. Volders *et al.* assessed quality of life using EORTC-QLQ- C30 and the breast cancer module QLQ-BR23 questionnaire. Operative time was mentioned in 2 studies only. Doyle *et al.* assessed the use of High frequency ultrasound in assessment of margin using 50 MHz transducers

Study name	Study design	Number of patients	Clear margin	Volume of breast removed	Clear Margin Definition
Esgueva <i>et al.</i> , 2019	Prospective RCT	N=214 IOUS=148 WL=66	IOUS 94.5% WL 84.78%	IOUS=43.24 cc WL=55.68 cc P=0.02	<5 mm by US & (<2mm) or positive margins by pathology.
Fisher <i>et al.</i> , 2011	Non-Randomised trial	IOUS =73 PGE= 124	IOUS=7 (10%) PGE=20(16%)	IOUS=2 cm3 PGE= 1.5cm3 P=<0.05 Tumour not lump	tumor cells at, or very close to (<2 mm), the resection margin.
Moore <i>et al.</i> , 2001	RCT	IOUS=27 PGE=24	IOUS=26(96.5%) PGE=17(70%)	IOUS=104+/- 8 cm3 PGE=114+/-5.6 cm3 P= NS	any margin where tumor cells were microscopically visible on final histopathologic evaluation.
Karanlik <i>et al.</i> , 2015	Prospective cohort	IOUS=84 PGE=80	IOUS=79(94%) PGE=66(17%)	IOUS=89.9(53.9) cm3 PGE=108.1(63.4) cm3 P=NS	margin was reported to be positive or less than 5 mm macroscopically
Larson <i>et al.</i> , 2017	Retrospective cohort	RG=89 PGE=92	IOUS=26(29.2%) PGE=38(41.3%)	N/A	<2 mm for DCIS or tumor or ink for invasive cancer.
Ramos <i>et al.</i> , 2012	observational non-randomized	IOUS=225	IOUS=24(10.6%) 21 had re-excision in same surgery	IOUS=26.1gm (5-110)	not clear or were close to the tumour (3 mm)
Volders <i>et al.</i> , 2016	Prospective RCT	IOUS=65 PGE=69	IOUS=63(97%) PGE=57(83%) P=0.009	IOUS=38 cc PGE=53 cc P=0.0004	surgically-feasible healthy tissue margin of up to an arbitrarily chosen 1 cm

Study name	Cosmesis (patient satisfaction)	Second surgery	Follow up	Surgical time	Additional Procedure
Esgueva <i>et al.</i> 2019	N/A	IOUS=8 WL=10 RR=3.13(CI 95% 1.17-8.33)	IOUS=51.22(36.07-62.51) WL=69.85(26.45-98.58)	IOUS=mean40.58 min WL=53.86	IOUS=4/8 Mastectomy WL=6/10 Mastectomy
Fisher <i>et al.</i> , 2011	N/A	IOUS=17(23%) PGE=31(25%)	N/A	N/A	N/A
Moore <i>et al.</i> , 2001	IOUS=25/27 PGE=22/24	IOUS=1 (3.5) PGE=7(29)	N/A	IOUS=106+/-37 PGE=121+/-39	N/A
Karanlik <i>et al.</i> , 2015	IOUS=67/71 PGE= 55/60P=NS	IOUS= 5(6%) PGE=14(7%)	N/A	N/A	N/A
Larson <i>et al.</i> , 2017	N/A	IOUS=9(10%) PGE=17(18.3%) P=NS	N/A	N/A	Mammogram for PGE
Ramos <i>et al.</i> , 2012	N/A	IOUS=3(1.3%)	20 Months	N/A	2 Mastectomy
Volders <i>et al.</i> , 2016	IOUS=89% PGE=79%	IOUS=1(2%) PGE=3(4%)	41 months	N/A	Mastectomy IOUS=0 PGE=5



and results from high-frequency ultrasonic measurements of human breast tissue specimens indicate that characteristics in the ultrasonic attenuation, spectra, and cepstra can be used to differentiate between normal, benign, and malignant breast pathologies. Another aspect of development is usage of 3D Ultrasound, use of this system has the potential to reduce the number of re-excision surgeries that these patients undergo which delays their systemic chemotherapy with potentially negative long-term outcomes.

Clear margin: Definition of and evaluation of surgical margins is essential for oncological sound treatment of breast cancer (Wazer *et al.*, 1992). IOUS seems to improve the rate of clear margins and reduce re-excision rate for invasive disease. Larson *et al* had slightly different results as in his study he used mammogram as well as US. On the other hand, other methods for assessment of margin was compared in 6 studies. And margin clearance varied between 70% to 84%. There were 675 patients of all 711 patients in these studies who had clear margin representing 94.9%. clear margin definition was variable between different studies, Esgueva *et al* definition was: (close (≤ 2 mm) or positive margins) and this is considered involved margin and warrant re-excision. This was also used by Fisher *et al.* for Larson *et al* tumour on ink is considered involved margin for invasive cancer and for Ductal carcinoma in situ (DCIS) < 2 mm from margin is involved margin. Moore *et al* had similar principle a positive margin was defined as any margin where tumour cells were microscopically visible on final histopathologic evaluation. For Ramos *et al* positive margin if the margin 3mm close to the tumour. Volders *et al* defined clear margin in their study as “no tumour cells at the margin” however, they aimed to remove at least 1 mm of healthy tissue on all margins.

Karanlik *et al* reported positive margin if involved or less than 5 mm from tumour margin. As mentioned, the concept of clear margin was variable between authors in different studies from tumour on ink to 5mm, and till now there is controversy on definition of safety margin for invasive breast cancer, despite most surgeon agree that no tumor cell at margin is sufficient for a clear margin this cannot be generalised. This variability in margin definition in each study can alter the results and the outcomes as well, in another word, one patient could have described as having involved margin in one study and that same patient can have clear margin in another study and avoid second surgery. Another difference in these studies, was the ultrasound machine and US probe used to assess intra-operative margin. Moore *et al* used 7.5-MHz linear-array ultrasound while Karanlik *et al* multifrequency 10-MHz linear array ultrasound probe. The US machine used by Ramos *et al* was 6-12 MHz high-frequency linear array transducer (Falcon Ultrasound Scanner, B-K Medical Systems, MA 01960, USA). Volders *et al* used a 14 MHz ultrasonography probe (Toshiba Viamo, Tokyo, Japan). Esgueva *et al* used Esaote MyLab25Gold (Genova, Italy). And Fisher *et al* Sonosite Micromax device (Bothell, WA) but both did not mention the probe size. Larson *et al* mentioned that L-shaped probe was used with no further details. The implication of using variable US machines and probes may result in different outcomes, as the sensitivity of each probe is different, and interpretation of the sonographic findings based on each machine. Another fact that should be considered is the experience of the US operator and his experience as US is operator dependent and results may vary

between different individual. Another point to take in consideration is the time gap between these studies as first study included in the review was done 2001 while the last study was published in 2019, during these 18 years the advancement and the technology behind US could have affected the outcome with relatively more advanced US equipment.

Second surgery: Less patients had further excision in IOUS group across all studies. However, percentage of patients having second surgery was variable among different studies, Ramos *et al* had only 3 out of 225 cases that had second surgery representing 1.3% that was the lowest second surgery rate among the chosen studies. Volders *et al* had similar results with second surgery rate about 2%, Moore *et al* had 3.5% second surgery rate. Esgueva *et al* and Karanlik *et al* second surgery rate of 5.4% and 6 % respectively. The remaining 2 studies had over 10 % second surgery Larson *et al* had 10% and Fisher *et al* was the highest 23%. Second surgery rate was insignificant from other methods of assessment of intra-operative margin in all studies apart from Moore *et al.* Patients who had subsequent mastectomy were mentioned in 3 studies with a total number of 17 patients having mastectomy 6 patients had mastectomy after using US and the other 11 when using other methods. IOUS as a tool for assessment of intraoperative margin can result in decreasing second surgery for involved margin, however at the moment there is no statistical difference between using ultrasound and other conventional methods, but this can be related to the small sample size of these studies. reducing the number of second surgery due to margin involvement can result in improved cosmetic outcome and patient satisfaction. In addition, it has financial implication by reducing the cost of second operation and decreasing overall hospital stay.

Removed breast volume & cosmetic outcome: IOUS would improve cosmesis by enabling the surgeon to position the incision on the breast optimally and minimize the resection of normal breast parenchyma (Moore *et al* 2001). Volders *et al*, Esgueva *et al* and Fisher *et al* showed that there is statistically significant reduction in the removed breast volume when using intra-operative US compared to other methods. Despite Moore *et al* and Karanlik *et al* showed that using US reduced amount of breast volume that was statistically non-significant. This is another benefit of using US in assessment of margin, as it resulted in decreasing amount of the breast volume removed. there is also evidence that the cosmetic result depends on the volume of breast excised and the number of reoperations performed (Wazer *et al.*, 1992). 3 studies commented on cosmetic outcome and patient satisfaction (Moore *et al*, Karanlik *et al* and Volders *et al*) 2 of those studies showed no noticeable difference in cosmetic outcome and patient satisfaction when comparing IOUS guided resection with palpation guided resection. Moore *et al* and Karanlik *et al* had non-significant difference for removed breast tissue using IOUS and PGE and hence there was no significant difference in cosmetic outcome, However, for Volders *et al* in the COBALT trial volume of breast tissue removed was significantly less in US group compared to PGE group and Cosmetic self-evaluation at 3 years when comparing 2 groups was significant with a P value < 0.001 . this is consistent with the fact that the more breast tissue removed the worse cosmetic outcome.

This is another advantage for using US to assess margin during surgery where it was noted that there is less breast tissue removed when using ultrasound and consequently better cosmetic outcome. However, 2 studies did not show any superiority in cosmetic outcome for IOUS group. This can be explained by using oncoplastic technique which is aesthetically appealing despite removing excess tissues. Another explanation is that cosmetic outcome was not affected by removing excess tissue is that patients had larger breast volume, hence the excess tissue removed will have trivial effect in cosmetic outcome as the percentage of removed breast tissue is the determinant not the exact volume, and this was not addressed in any of the studies.

Assessment of quality: The quality of the studies included in this systematic review was relatively poor 2 of the RCT scored one on Jadad score and the other scored 2 this score does not reflect the actual quality of the involved studies as it is technically difficult to design a double blinded study in surgery, which attributed to the low score. Other studies scored relatively better on Newcastle Ottawa Score two studies scored 5 and one study scored one and another scored 4, this numerical guide is helpful in assessment of the quality of each individual study and the main strength and weakness of each study and how to improve it in the future for example, follow up of the patients was not done in 3 of these studies and it would have markedly improved their score and quality if included in the study design.

Limitation

There are few limitations in this systematic review.

First, there was no uniformity in definition of positive margin in different studies, each study had its own definition of clear margin. Second, the limited number of RCT and variability of study design means that performing meta-analysis was not feasible.

Recommendations & implications

US is a safe and cheap tool that can be used to help surgeon in assessing intra-operative margin large RCT's need and meta-analysis need to be designed to show the efficacy of US as a modern technique for reducing margin involvement. From the studies that has been involved in this systematic review there is no strong evidence to recommend using routine US to assess intraoperative margin from the 7 studies involved in the systematic review only 3 were RCT's and they were of poor quality by Jadad score one study scoring 2 and the other two scored 1. Four of these studies showed IOUS superiority in assessing safety margin and three showed similar results to control group. Well-designed RCT's can help in proper evaluation of IOUS taking in consideration unified definition of clear margin. There is still a room for development for this technique with development in the industry of ultrasound machine, Another benefit of using this system will be the improved aim of the surgeon's resection directly to the tumour area, minimizing the unintended resection of large amounts of normal breast tissue, which has a large impact on the postoperative cosmetic appearance of the breast (DeJean *et al.*, 2010).

On the basis of this systematic review it is clear that Intra-operative ultrasound can decrease return to theatre and improve surgical margin as well as cosmetic outcome and patient satisfaction. On the other hand, ultrasound overestimated the pathology margins in most cases. Margin overestimation by ultrasound may lead the surgeon to incorrectly believe that the excised margins are inappropriate. The overestimation of the majority of the tumour margins may be explained in part by the tendency of ultrasound to underestimate the pathologic tumor diameter (Ngô *et al.*, 2007). Another possible factor that needs to be taken into account as a cause for overestimation of tumor margins by ultrasound is the compression of the specimen by the ultrasound probe during *ex vivo* examination of the margins (Karanlik *et al.*, 2015).

REFERENCES

- Ahmed M, Douek M. Intra-operative ultrasound versus wire-guided localization in the surgical management of non-palpable breast cancers: systematic review and
- Balch GC, Mithani SK, Simpson JF, Accuracy of intraoperative gross examination of surgical margin status in women undergoing partial mastectomy for breast malignancy. *Am Surg* 71:22-27, 2005; discussion 27-28
- Barnea Y, Inbal A, Barsuk D, Menes T, Zaretski A, Leshem D, *et al.* Oncoplastic reduction using the vertical scar superior-medial pedicle pattern technique for immediate partial breast reconstruction. *Can J Surg*. 2014;57(4): E134-40.
- Carla S. Fisher, MD, Fatema Al Mushawah, MD, Amy E. Cyr, MD, Feng Gao, PhD, and Julie A. Margenthaler, MD, FACS.: Ultrasound-Guided Lumpectomy for Palpable Breast Cancers *Ann Surg Oncol* (2011) 18:3198–3203
- Chakravorty A, Shrestha AK, Sanmugalingam N, Rapisarda F, Roche N, Querci Della Rovere G. How safe is oncoplastic breast conservation? Comparative analysis with standard breast conserving surgery. *Eur J Surg Oncol*. 2012;38(5):395-8
- Chan SW, Cheung PS, Lam SH. Cosmetic outcome and percentage of breast volume excision in oncoplastic breast conserving surgery. *World J Surg*. 2010;34(7):1447-52.
- Chang EI, Peled AW, Foster RD, Lin C, Zeidler KR, Ewing CA, *et al.* Evaluating the feasibility of extended partial mastectomy and immediate reduction mammoplasty reconstruction as an alternative to mastectomy. *Ann Surg*. 2012;255(6):1151-7.
- Clough KB, Ihrai T, Oden S, Kaufman G, Massey E, Nos C. Oncoplastic surgery for breast cancer based on tumour location and a quadrant-per-quadrant atlas. *Br J Surg*. 2012;99(10):1389-95.
- Clough KB, Soussaline M, Campana F, Salmon RJ. Mammoplasty combined with irradiation: conservative treatment of cancers located in the lower quadrants. *Ann ChirPlastEsthet*. 1990;35(2):117–22.
- Esbona K, Li Z, Wilke LG. Intraoperative imprint cytology and frozen section pathology for margin assessment in breast conservation surgery: a systematic review. *Ann Surg Oncol*. 2012;19:3236–3245.
- Ferlay J, Soerjomataram I, Dikshit R, *et al.* Cancer incidence and mortality worldwide: sources, methods and major patterns in GLOBOCAN 2012. *Int J Cancer* 2015;136:E359–386.

- Fisher B, Jeong JH, Anderson S, Bryant J, Fisher ER, Wolmark N. Twenty-five-year follow-up of a randomized trial comparing radical mastectomy, total mastectomy, and total mastectomy followed by irradiation. *N Engl J Med*. 2002;347(8):567-75.
- Fukamachi K, Ishida T, Usami S, *et al*. Total-circumference intraoperative frozen section analysis reduces margin-positive rate in breast-conservation surgery. *Jpn J Clin Oncol*. 2010;40:513-520.
- Georgian-Smith D, Taylor KJW, Madjar H. Sonography of palpable breast cancer. *J Clin Ultrasound* 2000; 28:211-216
- Hasan Karanlik, IlkerOzgur, DilekSahin³, Merdan Fayda, Semen Onder and Ekrem Yavuz Intraoperative ultrasound reduces the need for re-excision in breast-conserving surgery *World Journal of Surgical Oncology* (2015) 13:321
- Houssami N, Macaskill P, Marinovich ML, *et al*: The association of surgical margins and local recurrence in women with early-stage invasive breast cancer treated with breast-conserving therapy: A meta-analysis. *Ann Surg Oncol* 21: 717-730, 2014
- Iwuchukwu OC, Harvey JR, Dordea M, Critchley AC, Drew PJ. The role of oncoplastic therapeutic mammoplasty in breast cancer surgery--a review. *Surg Oncol*. 2012;21(2):133-41.
- Jadad AR, Moore RA, Carroll D, *et al*. Assessing the quality of reports of randomized clinical trials: is blinding necessary? *Controlled Clin. Trials* 1996; 17: 1-12.
- Jorns JM, Visscher D, Sabel M: Intraoperative frozen section analysis of margins in breast conserving surgery significantly decreases reoperative rates: One- year experience at an ambulatory surgical center. *Am J Clin Pathol* 138:657-669, 2012
- Judy C. Boughey, MD, Gary L. Keeney, MD, Paul Radensky, MD, JD, Christine P. Song, MPH, and Elizabeth B. Habermann, PhD Economic Implications of Widespread Expansion of Frozen Section Margin Analysis to Guide Surgical Resection in Women With Breast Cancer Undergoing Breast-Conserving Surgery DOI: 10.1200/JOP.2015.005652;: 2016 *Journal Of Oncology Practice (J Oncol Pract)* 2016 Apr; Vol. 12 (4), pp. e413-22. Date of Electronic Publication Feb 23
- Judy C. Boughey, MD, Gary L. Keeney, MD, Paul Radensky, MD, JD, Christine P. Song, MPH, and Elizabeth B. Habermann, PhD : Economic Implications of Widespread Expansion of Frozen Section Margin Analysis to Guide Surgical Resection in Women with Breast Cancer Undergoing Breast-Conserving Surgery. *Journal of Oncology Practice* 2016 Apr; Vol. 12 (4), pp. e413-22. Date of Electronic Publication: 2016 Feb 23
- Lauricica R. Intraoperative assessment of the breast: guidelines and potential pitfalls. *Arch Pathol Lab Med*. 2005;129(12):1565-74.
- Lee Martin: Oncoplastic breast surgery A guide to good practice. *European journal of surgical oncology*. 2007 volume 33 s1-s23
- Losken A, Dugal CS, Styblo TM, Carlson GW. A meta-analysis comparing breast conservation therapy alone to the oncoplastic technique. *Ann Plast Surg*. 2014;72(2):145-9
- Losken A, Pinell-White X, Hart AM, Freitas AM, Carlson GW, Styblo TM. The oncoplastic reduction approach to breast conservation therapy: benefits for margin control. *Aesthet Surg J*. 2014;34(8):1185-91.
- Makuuchi M, Torzilli G, Machi J. History of intra-operative ultrasound. *Ultrasound Med Biol* 1998; 24:1229-1242.
- Margenthaler JA, Gao F, Klimberg VS: Margin index: A new method for prediction of residual disease after breast-conserving surgery. *Ann Surg Oncol* 17:2696-2701, 2010
- McCulley SJ, Macmillan RD. Therapeutic mammoplasty: analysis of 50 consecutive cases. *Br J Plast Surg*. 2005;58(7):902-7.
- meta-analysis. *Breast Cancer Res Treat*. 2013; 140:435-46.
- Moran MS, Schnitt SJ, Giuliano AE, *et al*: Society of Surgical Oncology-American Society for Radiation Oncology consensus guideline on margins for breast-conserving surgery with whole-breast irradiation in stages I and II invasive breast cancer. *Ann Surg Oncol* 21:704-716, 2014
- Ngô C, Pollet AG, Laperrelle J, Ackeman G, Gomme S, Thibault F, *et al*. Intraoperative ultrasound localization of nonpalpable breast cancers. *Ann Surg Oncol*. 2007;14(9):2485-9.
