



## REVIEW ARTICLE

### EVALUATION OF THYROID ABNORMALITIES USING ULTRASONOGRAPHY AND RADIONUCLIDE SCINTIGRAPHY

<sup>1,2</sup>Amel Bushra A. Ahmed, <sup>1,3</sup>Mohamed Yousef and <sup>1</sup>Salah Ali Fadhlalah

<sup>1</sup>College of Medical Radiological Science, Sudan University of science and Technology, Sudan Khartoum

<sup>2</sup>Fujairah Hospital, Fujairah, UAE

<sup>3</sup>College of Batterjee Science College, Radiological Science, Jeddah, Saudi Arabia

#### ARTICLE INFO

##### Article History:

Received 07<sup>th</sup> April, 2018  
Received in revised form  
04<sup>th</sup> May, 2018  
Accepted 18<sup>th</sup> June, 2018  
Published online July 30<sup>th</sup>, 2018

##### Keywords:

Ultrasound,  
Scintigraphy,  
Thyroid nodules.

#### ABSTRACT

The main aim of this study was to evaluate the thyroid abnormalities using ultrasound and scintigraphy in order to avoid radiation hazards

**Methods:** A The study population consisted of 173 patients were seen by surgeons and medical doctors, were diagnosed clinically ashaving thyroid issues, and referred to Nuclear Medicine and Radiology Department, Fujairah hospital for thyroid scintigraphy and neck ultrasound during the period from Jan 10, 2016 to June 30, 2018. All patients Thyroid function test were done before coming to radiology department. So all results were comparing with the thyroid function tests (TFT) results.

**Results:** thyroid scintigraphy and ultrasound reached the almost same imaging findings in patients with thyroid abnormality. Ultrasonography compared to nuclear medicine scintigraphy, Ultrasound detected 93.6% (162 patients) more than nuclear medicine 90.3% (157 patients) by 3.3 %. Ultrasonography was found to be an appropriate study in the detection of thyroid abnormality. Both US and thyroid scintigraphy have diagnosed the thyroid gland abnormality and suggested the diagnosis of others disorders in all other patients.

**Conclusion:** Both modalities revealed almost similar results. Ultrasound has the additional advantages of being non-ionizing radiation and accurately localizes and characterizes the thyroid abnormalities. Ultrasound examination should be obtained routinely for patients with suspected thyroid diseases and scintigraphy is reserved for selected cases.

*Copyright © 2018, Amel Bushra et al. This is an open access article distributed under the Creative Commons Attribution License, which permits unrestricted use, distribution and reproduction in any medium, provided the original work is properly cited.*

## INTRODUCTION

A thyroid disease is a medical condition impairing the function of the thyroid. Different thyroid diseases include Hashimoto's thyroiditis, hyperthyroidism and hypothyroidism. These diseases have a large range of symptoms and affect all ages. The most common thyroid disorders include Hashimoto's disease, Graves' disease, goiter, and thyroid disorders.

## MATERIALS AND METHODS

A total of 173 patients were seen by surgeons and medical doctors as having thyroid issues, and referred to Nuclear Medicine and Radiology Department, Fujairah hospital for thyroid scintigraphy and neck ultrasound during the period from Jan. 10, 2016 to June. 30, 2018. The thyroid scintigraphy obtained 10-20 minutes after intravenous injection of 37-111MBq of sodium pertechnetate Tc-99m using a LEHR

(low energy high resolution collimator-equipped gamma-scintillation camera. All thyroid scintigraphies were interpreted by one Nuclear Medicine Physician. For ultrasound, all patients were scanned supine with their necks hyperextended using a 7.5-10-MHz transducer. All patients underwent neck ultrasound by one expert radiologist. The data analyzed using the SPSS program.

### Ultrasound Examination

For ultrasound a high-frequency (6–15 MHz) linear transducer is used. The highest frequency is used while still allowing adequate sonographic penetration. All patients are examined in supine position with hyperextended neck, using a high frequency linear-array transducer (6 -15 MHz) that provides adequate penetration and high resolution image. Scanning is done both in transverse and longitudinal planes. Real time imaging of thyroid lesions is performed using both gray-scale and color Doppler techniques. The imaging characteristics of a mass (viz. location, size, shape, margins, echogenicity, contents and vascular pattern) should be identified

\*Corresponding author: Amel Bushra A. Ahmed,  
College of Medical Radiological Science, Sudan University of science and Technology, Sudan Khartoum  
Fujairah Hospital, Fujairah, UAE.

## Nuclear medicine examination

Technetium 99m pertechnetate ( $^{99m}\text{TcO}_4^-$ ) is a used radioactive label for thyroid scanning. Injection Technique a fine Butterfly needle (gauge 23-25 according to patient's age) is recommended. Technetium-99m when used as a radioactive tracer can be detected in the body by medical equipment (gamma cameras). It is well suited to the role because it emits readily detectable 140 keV gamma rays (these are about the same wavelength as emitted by conventional X-ray diagnostic equipment), and its half-life for gamma emission is 6.0058 hours (meaning 93.7% of it decays to  $^{99}\text{Tc}$  in 24 hours). The "short" physical half-life of the isotope and its biological half-life of 1 day (in terms of human activity and metabolism) allows for scanning procedures which collect data rapidly, but keep total patient radiation exposure low. The same characteristics make the isotope suitable only for diagnostic but never therapeutic use.

## Data Collection and Analysis

Data will be collected in tabulated database sheet and will be analyzed by SPSS. The data included the age, gender, us finding and Nuclear medicine scintigraphy findings

## RESULTS

**Table 1. Numbers of male and female patients**

Patients	Numbers
Male	24
Female	149
Total numbers	173

**Table 2. Numbers of normal and abnormal patients in each test**

Patients	Normal	Abnormal
Ultrasound	11	162
Nuclear medicine	16	157
Total numbers	27	319

**Table 3. Patient's ages**

Age group	Numbers of patients
0 > 10	1
10 > 20	13
20 > 30	35
30 > 40	50
40 > 50	46
50 > 60	13
60 > 70	15
Total number of patients	173

**Table 4. The Numbers of normal patients and patients with different thyroid disorder in each test**

Thyroid disorders	Ultrasound test	NM test
Autonomous Nodule	0	2 (1.1)
nodular goiter- NTG , TNG	30 (17.3%)	30 (17.3%)
Goiter	1 (0.57)	11 (6.4%)
Grave disease	15 (8.7%)	13 (7.5%)
Multinodular goiter	83 (48%)	43 (24.8%)
Thyroiditis	25 (14.5%)	20 (11)
Thyroid nodule	2 (1.1)	2 (1.1)
Toxic multinodular goiter	3 (1.73%)	21
Toxic goiter	3 (1.73%)	15 (8.7%)
Normal	11 (6.4%)	16 (9.2%)
total	173	173

**Table 5. Nodules site in both tests (thyroid scintigraphy and thyroid ultrasound)**

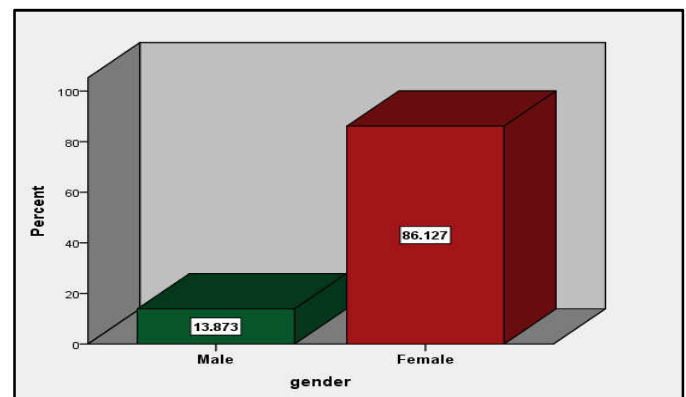
Nodule site	Nuclear medicine	Ultrasound
Lt lobe	63	118
Rt lobe	80	114
isthmus	19	22
Total	162	254

**Table 6. Thyroid size in both tests (thyroid scintigraphy and thyroid ultrasound)**

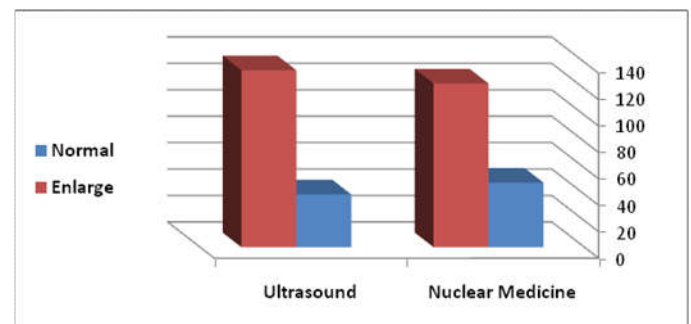
size	Nuclear medicine	Ultrasound
Normal	49 (28%)	40 ( 23%)
Enlarge	124 (72%)	133 (77%)
Total	173 (100%)	173 (100%)

**Table 7. Shows nodule site in both tests**

Nodules	Nuclear medicine	Ultrasounds
Nodule	53	26
Multi nodules	49	109
total	102	135



**Figure 1. Shows Numbers of male and female patients**



**Figure 2. Shows the thyroid gland sizes in both tests**

## DISCUSSION

Thyroid gland ultrasound examination has been playing an important role in the evaluation of its pathologies, mainly due to its feasibility, low cost, absence of morbidity, besides the high resolution of the most modern equipment. Nuclear scintigraphy is commonly used for evaluation of physiologic thyroid function and for identification of metabolically active and inactive nodules. Thyroid US was performed by an Toshiba Ultra sound machine scanner with a 6- to 15-MHz bandwidth transducer. Compound imaging was performed with Color Doppler in all cases. Sonographic classification based on sonographic features was performed by one experienced sonographer. Size was measured as the longest diameter.

Sonographic features included echogenicity, margin, calcifications, and shape, based on our previous publication. Color Doppler imaging was routinely obtained. Echogenicity was classified as hyper echogenicity, isoechogenicity, hypo echogenicity, and hetroechogenicity. When the echogenicity was similar to thyroid parenchyma, the nodule was classified as isoechogenic. Calcifications were categorized as calcifications, or none. Mixed nodules, composed of both cystic and solid portions, were classified according to the solid portion. Nuclear medicine thyroid scan was performed by an Bright View gamma camera. Nuclear medicine classification based on distribution of the radioisotopes through the thyroid. Features were performed by one experienced nuclear medicine technologist. Size was measured as the whole diameter. The features included, homogeneity, uptake, count per pixel, and area. The study population consisted of 176 patients were seen by surgeons and medical doctors as having thyroid issues, and referred to Nuclear Medicine and Radiology Department, Fujairah hospital for thyroid scintigraphy and neck ultrasound during the period from Jan. 10, 2016 to June. 30, 2018. All patients Thyroid function test were done before coming to radiology department. So all results were comparing with the TFT results. Thyroid ultrasound, nuclear medicine thyroid scintigraphy and demographic data are presented in Tables and figures for this study revealed that, among this 173 patients 86% were female(149) and 14% were male (24), table (4-1).The mean age of patients was 38 years, table (4-3). Thyroid ultrasound scan results were normal in 6.4 % (11 patients) and abnormal in 93.6 % (162 patients), while thyroid nuclear medicine scan were reported as normal in 6.4 % (16 patients) and abnormal in 91% (157 patients) table (4-2). In this study table (4-4) shows that ultrasound examination is able to detect multi nodules in 83 of the patients while nuclear medicine scan is able to detect only 43 patients. However, when the nodule is solitary, the ultrasound and the nuclear medicine thyroid scan are same in detecting it. And if multi nodules are toxic, nuclear medicine is better in detecting it (21 patients) comparing to Ultrasound (3 patients). In diagnosis of Autonomous nodule nuclear scan was able to detect it while ultrasound couldn't detect it. In graves' disease both modalities were near each other's, Ultrasound (15 patients) 8.7% and nuclear medicine (13 patients) 7.5% in detecting it. For thyroiditis ultrasound was better than nuclear medicine, (25 patients) 14.4% to (20 patients) 11%. However in diagnosis of toxic goiter nuclear medicine thyroid scan was better than ultrasound, (15 patients) 8.7% to (3 patients) 1.73%. Table (4-5) shows the nodule sites in both tests. It was more nodules in ultrasound, in the Rt lobe, Lt lobe and isthmus, 114, 118, 22, while it was, 80, 63, 19 in the thyroid nuclear medicine scan. Table (4-6) shows that the thyroid gland size if its enlarge or not. And it was enlarge by (133 patients) 77% of patients in ultrasound, and normal in (40 patients) 23 % of all cases. In nuclear medicine thyroid scan it was enlarge in (124 patients)72% of patients and normal in (49 patients) 28 % of all cases. Table (4-7) shows the ability of both tests, thyroid ultrasound and nuclear medicine thyroid scan, in detecting nodules. Nuclear medicine was good in detecting solitary nodules in 53 patients more than ultrasound which detected in only 26 patients. Put when patient have multiple nodules, ultrasound was best in detecting nodules in 109 patients compare to nuclear medicine which detect nodules in only 49 patients. That means ultrasound have more sensitivity and specify than nuclear medicine in diagnosis of multinodular goiter diseases. In all cases the ultrasound made the diagnosis in 93.6% (162 patients) more than nuclear medicine 90.3% (157 patients) by 3.3 %, Table (4-4). In spite

of some limitations of this, ultrasound examination plays an important role for patients in diagnosis of thyroid abnormalities, especially in thyroid nodules.

**Limitations of this study:** Ultrasonography is not always able to separate benign from malignant nodules with complete certainty. In suspicious cases, a tissue sample is often obtained by biopsy for microscopic examination. It is recognized that offers little or no diagnostic information for thyroid diseases.

### Conclusion and Recommendation

Ultrasound can be able to evaluate the thyroid abnormalities especially multinodular goiter and thyroiditis and graves diseases. And have same ability as nuclear medicine scintigraphy in detecting solitary thyroid nodules, nodular goiter. When the ultrasound examination is performed by an experienced operator with high resolution equipment, it presents good accuracy in detecting thyroid abnormalities. Consequently, ultrasound can be used for evaluation and follow up. Thyroid scintigraphy examination would be indicated for patients with alterations in ultrasound examination or when there is a higher possibility of detecting new goiter diseases because of it is his ability of making it is diagnosis.

### Recommendation

- Thyroid ultrasound is a highly sensitive and specific method to detect thyroid diseases.
- Thyroid ultrasound should be routinely done in patients with abnormal thyroid function tests
- Thyroid ultrasound can plays important role for patient with thyroid abnormalities if the sonographer is well trained.

**Acknowledgement:** I would like to express my deep gratitude to Dr. mohammedomer for his invaluable guidance and fruitful discussion and comments through this work. I would like to thank my wonderful family for being supportive, patient and for helping me survive all the stress from this tow years and not letting me give up. I would like to thank my wonderful friend Dr Gihad K. Hamid, KING ABDULLA MIDICAL CITY KSA, for being supportive, and for helping me with his valuable guidance.

### REFERENCES

- Agur AMR, et.al. 1999. Grant's Atlas of Anatomy. 10th Ed. Lippincott Williams and Wilkins. London, UK.
- Bastin, S. et al. 2009. "Role of ultrasound in the assessment of nodular thyroid disease: radiology—review article," *Journal of Medical Imaging and Radiation Oncology*, vol. 53, no. 2, pp. 177–187.
- Berbel P, Navarro D, Ausó E, Varea E, Rodríguez AE, Ballesta JJ, Salinas M, Flores E, Faura CC, et al. 2010. "Role of late maternal thyroid hormones in cerebral cortex development: an experimental model for human prematurity.
- Boron, WF., Boulapep, EL. 2012. Medical Physiology(2nd ed.. Philadelphia: Saunders. p. 1052
- Bowen, R. 2000. "Thyroid Hormone Receptors". Colorado State University, USA

- Burkitt, H., Quick, C. and Gatt, D. Essential surgery, 1996. Edinburgh : Churchill Livingstone.
- Cai XJ, et al. 2011. Ultrasound-guided fine needle aspiration cytology in the diagnosis and management of thyroid nodules. *Cytopathology, Yonsei Med J.*, 52(5): 838–844.
- Cappelli C. et al. 2006. Thyroid nodule shape suggests malignancy. *Eur J Endocrinol.*, 155(1):27–31.
- Charles S. Odwin, et al. 2012. "LANG REVIEW, Ultrasound Examination" fourth edition, New York, USA.
- Cooper DS, et al. 2006. Management guidelines for patients with thyroid nodules and differentiated thyroid cancer. *Thyroid.*, 16(2):109–142.
- Corwin, Elizabeth, 2008, Hand book of pathophysiology, 3ed Edition, Lippincott Williams & Wilkins, Ohio, USA.
- Corwin, Elizabeth, 2008, Hand book of pathophysiology, 3ed Edition, Lippincott Williams & Wilkins, Ohio, USA.
- Courtney Townsend, R. Daniel Beauchamp, B. Mark Evers, Kenneth L. Mattox (27 July 2004); "The 17th edition of Townsend: Sabiston Textbook of Surgery represents an ... Publisher: Saunders; 17 edition London, UK
- Ezzat S, et al. 1996. Thyroid incidentalomas. Prevalence by palpation and ultrasonography. *Arch Intern Med.*, 154(16):1838–1840.
- Fatourech V. 2009. "Subclinical hypothyroidism: an update for primary care physicians". *Mayo Clin. Journal of Medicine*, 18(1):30.
- Fawcett, Don; Jensch, Ronald, 2002. Bloom & Fawcett's Concise Histology. New York: Arnold Publishers. pp. 257–258
- Frates MC, et al. 2003), Can color Doppler sonography aid in the prediction of malignancy of thyroid nodules?. *J Ultrasound Med.*, 22:127–131.
- Frates MC, et al. 2005. Management of thyroid nodules detected at US: Society of Radiologists in Ultrasound consensus conference statement. *Radiology.*, 237(3):794–800.
- Fred A. Mettler, 17 Jan 2012, Essentials of Nuclear Medicine Imaging, 6th edition, USA, Philadelphia
- Gharib H, et al. 2005. "Subclinical thyroid dysfunction: a joint statement on management from the American Association of Clinical Endocrinologists, the American Thyroid Association, and the Endocrine Society". Volume 90, 581–585.
- Gharib H, et al. 2006. American Association of Clinical Endocrinologists and Associazione Medici Endocrinologi medical guidelines for clinical practice for the diagnosis and management of thyroid nodules. *Endocr Pract.*, 12:63–102.
- Gharib H, Goellner JR. 1993. Fine-needle aspiration biopsy of the thyroid: an appraisal. *Ann Intern Med.*, 118:282–9.
- Giannini AJ, et al. 1987. "Blunting of TSH response to TRH in chronic cocaine and phencyclidine abusers". *J Clin Psychiatry*, 48 (1): 25–6
- Giannini AJ, Malone DA, Loiselle RH, Price WA. 1987. "Blunting of TSH response to TRH in chronic cocaine and phencyclidine abusers". *J Clin Psychiatry.*, 48 (1): 25–6.
- Goldsmith, Stanley J. 1997. "Endocrine System." In Nuclear Medicine, ed. D. R. Bernier et al. St. Louis, MO: Mosby.
- Gray H, Lewis WH. 2000. Gray's Anatomy of the Human Body. 20th Ed. New York.
- Gulcelik NE, et al. 2008. Risk of malignancy in patients with follicular neoplasm: predictive value of clinical and ultrasonographic features. *Arch Otolaryngol Head Neck Surg.* 134(12):1312–1315.
- Harnsberger HR, Osborn AG, Ross J et-al. 2006. Diagnostic and Surgical Imaging Anatomy. Lippincott Williams & Wilkins.
- Harvey A. Ziessman, et al. 04 April 2013, Nuclear Medicine: The Requisites, 4th edition, USA, Philadelphia.
- Jansen J, Friesema EC, Milici C, Visser TJ. 2005. "Thyroid hormone transporters in health and disease"
- Khoo ML, Asa SL, Witterick IJ, Freeman JL. 2002. Thyroid calcification and its association with thyroid carcinoma. *Head Neck* ; 24: 651–655.
- Kim EK, et al. 2002. New sonographic criteria for recommending fine-needle aspiration biopsy of nonpalpable solid nodules of the thyroid. *AJR Am J Roentgenol.*, 178:687–91.
- Klingensmith, William C. III, Dennis Eshima, and John Goddard. Nuclear Medicine Procedure Manual 2000–2001. Englewood, CO: Oxford Medical Inc., 2000.
- Lee KY, Huang SM, Li S, Kim JM. 2009. Identification of differentially expressed genes in papillary thyroid cancers. *Yonsei Med J.*, 50:60–7.
- Machi J, Staren ED. 2005. Ultrasound for Surgeons. Lippincott Williams & Wilkins.
- Marqusee E, et al. 2005. Usefulness of ultrasonography in the management of nodular thyroid disease. *Ann Intern Med.* 133(9):696–700.[PubMed]
- Mazzaferrri EL, et al. 1998. Solitary thyroid nodule: diagnosis and management. *Med Clin North Am.*, 72:1177–211.
- Melmed, S., Polonsky, KS., Larsen, PR., Kronenberg, HM. 2011. Williams Textbook of Endocrinology (12th ed.. Saunders. p. 331.
- Moore, K. and Agur, A. 2007. Essential clinical anatomy. Philadelphia: Lippincott Williams & Wilkins. ([http://fitsweb.uhc.edu/student/selectives/Luzietti/Thyroid\\_anatomy.htm](http://fitsweb.uhc.edu/student/selectives/Luzietti/Thyroid_anatomy.htm))
- Palmer, P.E.S 1995. Manual of Diagnostic Medical Ultrasound, California USA.
- Papini E, Guglielmi R, Bianchini A, et al. 2004. Risk of malignancy in nonpalpable thyroid nodules: predictive value of ultrasound and color Doppler features. *J Clin Endocrinol Metab.*, 87:1941–1946. CrossRef, Medline
- Peccin S, de Castro JA, Furlanetto TW, et al. 2005. Ultrasonography: is it useful in the diagnosis of cancer in thyroid nodules?. *J Endocrinol Invest.*, 25:39–43. CrossRef, Medline
- Richard S. Snell, 2005, Clinical Anatomy for Medical Student – Mosby. 8<sup>th</sup>ed, New York, USA.
- Robbins SL, Kumar V, Abbas AK et-al. Robbins and Cotran pathologic basis of disease. W.B. Saunders Company. 2010.
- Solbiati L, Charboneau JW, Osti V, James EM, Hay ID. 2005. The thyroid gland. In: Rumack CM, Wilson SR, Charboneau JW, editors. Diagnostic Ultrasound. 3rd ed. Vol. 1. St. Louis, Missouri: Elsevier Mosby., pp. 735–70.
- Standring, S. 2008. Gray's anatomy. UK: Churchill Livingstone Elsevier.
- Stephen Nussey and Saffron Whitehead, 2001. The thyroid gland in Endocrinology:, Published by BIOS Scientific Publishers Ltd. I
- Surks MI, Hollowell JG. 2007. "Age-specific distribution of serum thyrotropin and antithyroid antibodies in the US population: implications for the prevalence of subclinical hypothyroidism". *J. Clin. Endocrinol.*
- Tan GH, Gharib H. 1997. Thyroid incidentalomas: management approaches to nonpalpable nodules discovered

- incidentally on thyroid imaging. *Ann Intern Med.*, 126(3):226–231.[PubMed]
- Ugurlu S, et al. 2008. Evaluation of thyroid nodules in Turkish population. *Intern Med.*, 47(4):205–209.[PubMed]
- Vikas Chaudhary and Shahina Bano1 *Indian J Endocrinol Metab.* Thyroid ultrasound 2013 Mar-Apr; 17(2): 219–227.
- Walter F., PhD. Boron, 2003. *Medical physiology: A cellular And Molecular Approach*, Chapter 48, "SYNTHESIS OF THYROID HORMONES" Elsevier/Saunders, pp. 1, 300 ISBN: 1-4160-2328-3
- Weissleder R, Wittenberg J, M.D. MG et-al. *Primer of Diagnostic Imaging*. Mosby. 2011.
- Wienke, J. R. et al. 2003. "Sonographic features of benign thyroid nodules: interobserver reliability and overlap with malignancy," *Journal of Ultrasound in Medicine*, vol. 22, no. 10, pp. 1027–1031.  
(<http://www.surgicalcore.org/>)  
<http://en.wikipedia.org/wiki/Technetium-99m>  
<http://www.insideradiology.com>  
<https://en.wikipedia.org>  
[https://en.wikipedia.org/wiki/Thyroid\\_disease](https://en.wikipedia.org/wiki/Thyroid_disease))

\*\*\*\*\*